

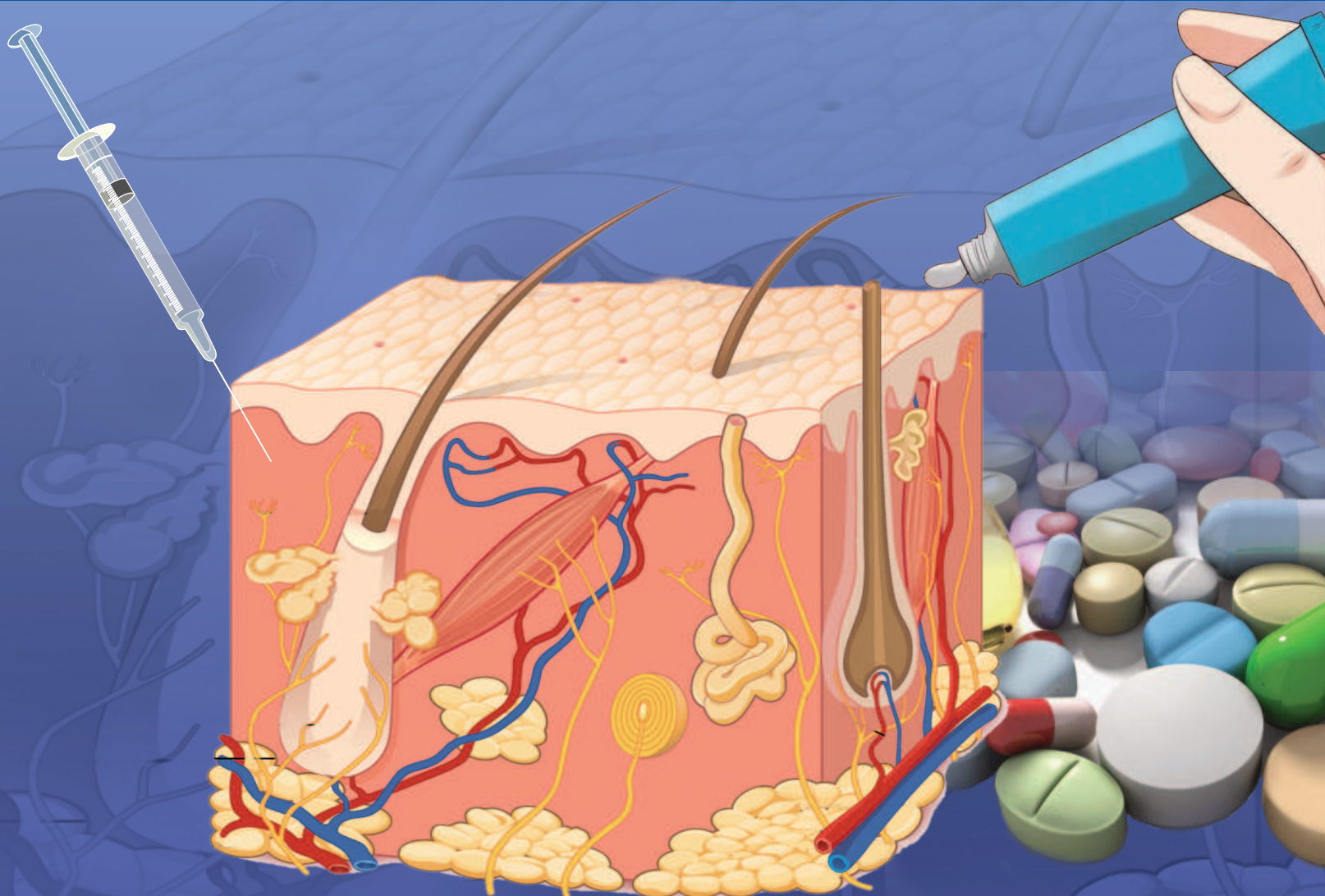
# IJDD Indian Journal of Drugs in Dermatology



An IADVL Publication

## In the Issue

- Editorial: Omalizumab in chronic Urticaria
- Bilastine: A novel antihistamine
- Oral levofloxacin versus minocycline in inflammatory acne vulgaris
- Doxycycline monotherapy in treating rhinoscleroma
- Plasmapheresis as adjuvant therapy for TEN
- Managing a side effect: Cyclosporine induced nephrotoxicity



## Combination of 308 nm Excimer Light with Topical Tacalcitol Ointment for Vitiligo Treatment

Sir,

Vitiligo is a common, acquired disorder of skin pigmentation that can significantly impact the quality of life. The disease affects approximately 1% of the population worldwide. Studies have demonstrated that the disfiguring nature of vitiligo causes high psychosocial morbidity.<sup>[1,2]</sup>

The 308 nm excimer laser is a newer treatment option that can yield impressive results in an abbreviated timeframe.<sup>[3]</sup> We tried excimer light therapy with a combination of tacalcitol ointment in 33 adult patients (18 females and 12 males mean age 31.1, age group 21–65-year duration of disease, and mean 3.1 years with a range of 2.1–5 years) with stable vitiligo. In 20 patients, lesions were located on the face while 4 patients had lesions on the neck, and in 9 cases, they were located on arms and legs. Exclusion criteria were lesions involving >20% of body surface area and unstable vitiligo.

We used GSD 308 nm excimer light machine by Shenzhen GSD technology Ltd.,<sup>®</sup> at wavelength of 308 nm and frequency of 50/60 Hz with a maximum irradiated area of 18.9 cm<sup>2</sup>. Before starting treatment, minimal erythema dose (MED) was calculated. Patients were asked to apply tacalcitol ointment at night and received 308 nm excimer light therapy twice a week. Initial dose of excimer light was determined based on MED with 72 h interval between two treatments. Light therapy was performed twice weekly until patients developed significant repigmentation. This was increased by 10% per visit until patients get repigmentation. Treatment dosages were then maintained or decreased by 10% depending on the severity of the side effects. None of the patients stopped treatment due to side effects of the laser therapy.

After 12 weeks of excimer light treatment, three patients were lost to follow-up. Repigmentation was graded according

to the percentage of repigmentation in the treated area: 75%–100% repigmentation, excellent (Score 3); 50%–74%, good (Score 2); 25%–49%, moderate (Score 1); and 1%–24%, poor and 0 (Score 0). Out of thirty patients receiving this light therapy, 12 showed excellent repigmentation, 8 showed a good response, 5 showed moderate repigmentation, and 5 showed poor repigmentation.

There were no major side effects noted. 1,24-Dihydroxyvitamin D<sub>3</sub> (tacalcitol), a Vitamin D<sub>3</sub> compound, has been used to treat T cell-mediated inflammatory skin diseases such as psoriasis, prurigo, and vitiligo. Sahu *et al.* found that topical tacalcitol potentiates the efficacy of Narrow Band ultraviolet B (UVB) as it enhances the extent of pigmentation, decreases time for repigmentation, and lowers the cumulative doses of narrow-band UVB.<sup>[4]</sup> In another study, combination of tacalcitol with sun exposure showed no additional advantages compared with sun exposure alone.<sup>[5]</sup> Concurrent topical tacalcitol application was shown to potentiate the efficacy of 308 nm monochromatic excimer light in the treatment of vitiligo, and that this combination achieved earlier pigmentation with a lower total dosage.<sup>[6]</sup>

One open trial showed that topical tacalcitol (1,24-dihydroxyvitamin D<sub>3</sub>), a Vitamin D<sub>3</sub> analog with a structure similar to that of calcipotriol (1,25-dihydroxyvitamin D<sub>3</sub>), combined with sunlight exposure can induce repigmentation.<sup>[7]</sup> Limitation of this study is a small number of patients and uncontrolled study.

We found this therapy useful in practice. However, double-blind randomized controlled studies with a larger sample are needed to confirm the encouraging small study results.

### Financial support and sponsorship

Nil.

## Conflicts of interest

There are no conflicts of interest.

**Kiran Godse, Gauri Godse<sup>1</sup>**

D Y Patil Hospital, <sup>1</sup>Shree Skin Centre, Nerul, Navi Mumbai, Maharashtra, India

**Address for correspondence:** Prof. Kiran Godse,  
D Y Patil Hospital, Nerul, Navi Mumbai, Maharashtra, India.  
E-mail: drgodse@hotmail.com

## REFERENCES

1. Linthorst Homan MW, Spuls PI, de Korte J, Bos JD, Sprangers MA, van der Veen JP, *et al*. The burden of vitiligo: Patient characteristics associated with quality of life. *J Am Acad Dermatol* 2009; 61:411-20.
2. Ongenaë K, Beelaert L, van Geel N, Naeyaert JM. Psychosocial effects of vitiligo. *J Eur Acad Dermatol Venereol* 2006;20:1-8.
3. Nicolaidou E, Antoniou C, Stratigos A, Katsambas AD. Narrowband ultraviolet B phototherapy and 308-nm excimer laser in the treatment of vitiligo: a review. *J Am Acad Dermatol* 2009;60:470-7.
4. Sahu P, Jain VK, Aggarwal K, Kaur S, Dayal S. Tacalcitol: A useful adjunct to narrow-band ultraviolet-B phototherapy in vitiligo. *Photodermatol Photoimmunol Photomed* 2016;32:262-8.
5. Rodríguez-Martín M, García Bustinduy M, Sáez Rodríguez M, Noda Cabrera A. Randomized, double-blind clinical trial to evaluate the efficacy of topical tacalcitol and sunlight exposure in the treatment of adult nonsegmental vitiligo. *Br J Dermatol* 2009; 160:409-14.
6. Lu-Yan T, Wen-Wen F, Lei-Hong X, Yi J, Zhi-Zhong Z. Topical tacalcitol and 308-nm monochromatic excimer light: A synergistic combination for the treatment of vitiligo. *Photodermatol Photoimmunol Photomed* 2006;22:310-4.
7. Katayama I, Ashida M, Maeda A, Eishi K, Murota H, Bae SJ. Open trial of topical tacalcitol [1 alpha 24(OH) 2D3] and solar irradiation for vitiligo vulgaris: Upregulation of c-Kit mRNA by cultured melanocytes. *Eur J Dermatol* 2003;13:372-6.

This is an open access journal, and articles are distributed under the terms of the Creative Commons Attribution-NonCommercial-ShareAlike 4.0 License, which allows others to remix, tweak, and build upon the work non-commercially, as long as appropriate credit is given and the new creations are licensed under the identical terms.

### Access this article online

#### Quick Response Code:



#### Website:

www.ijdd.in

#### DOI:

10.4103/ijdd.ijdd\_15\_18

**How to cite this article:** Godse K, Godse G. Combination of 308 nm excimer light with topical tacalcitol ointment for vitiligo treatment. *Indian J Drugs Dermatol* 2018;4:36-7.

© 2018 Indian Journal of Drugs in Dermatology | Published by Wolters Kluwer - Medknow